

# Topically delivered dissolved oxygen reduces inflammation and positively influences structural proteins in healthy intact human skin

Robert S Kellar, PhD,<sup>1</sup> Robert G Audet, BS,<sup>1</sup> David F Roe, PhD,<sup>2</sup> Lawrence A Rheins, PhD,<sup>3</sup> & Zoe Diana Draelos, MD<sup>4</sup>

<sup>1</sup>Development Engineering Sciences, Flagstaff, Arizona, USA

<sup>2</sup>AcryMed, Beaverton, Oregon, USA

<sup>3</sup>LAR Consulting, LLC, Scottsdale, Arizona, USA

<sup>4</sup>Department of Dermatology, Duke University School of Medicine, Durham, North Carolina, USA

## Summary

**Background** As oxygen is essential for wound healing and there is limited diffusion across the stratum corneum into the epidermis, we wanted to evaluate whether the topical delivery of a total dissolved oxygen in dressing form on intact human subject skin would improve clinical and histologic skin functioning.

**Aims** Fifty normal, healthy subjects completed a pilot clinical evaluation to assess the efficacy and tolerability of a dissolved oxygen dressing (OxygeneSys™-Continuous) to improve the health and appearance of intact skin.

**Methods** Clinical analysis was performed on 50 subjects; histological and gene expression analysis was performed on 12 of the 50 subjects to assess the effect of the dissolved oxygen dressing.

**Results** Clinical data demonstrate that the dressing is well tolerated, and several measures of skin health and integrity showed improvements compared with a control dressing site. Skin hydration measurements showed a statistically significant increase in skin hydration at 0–4, 4–8, and 0–8 weeks ( $P < 0.05$  at each time point). The blinded clinical investigator's grading of desquamation, roughness, and skin texture show significant decreases from baseline to the 8-week time point ( $P < 0.05$ ). The dressings were removed prior to the blinded clinical investigator's grading. These data were supported by the histological and gene expression studies, which showed a general reduction in inflammatory response markers and transcription products (IL-6, IL-8, TNF-alpha, MMP-1, and MMP-12), while facilitating a general increase in structural skin proteins (collagen I, elastin, and filaggrin). Additionally, p53 signals from biopsy samples support the clinical investigator's observations of no safety concerns.

**Conclusion** The data from this study demonstrate that the dressing has no deleterious effects and stimulates beneficial effects on intact, nonwounded skin.

**Keywords:** skin, topically dissolved oxygen, inflammation, structural proteins, filaggrin, aquaporin, aquaglyceroporin channel, AQP3

Correspondence: Dr. R S Kellar, Development Engineering Sciences, 708 N. Fox Hill Rd., Flagstaff, AZ 86004, USA. E-mail: rskellar@des-company.com

Accepted for publication January 15, 2013

## Introduction

Skin, the largest organ serves many functions, including protection from external environmental insults such

as pathogenic organisms, UV radiation, regulation of water and temperature and participating in the immune system.<sup>1</sup> Skin health is dependent on a number of fluctuating physiologic mechanisms. Many of these physiologic processes are compromised with age. For example, wound healing is significantly compromised in older subjects.<sup>1</sup> If left untreated, these wounds can become chronic in nature and present serious clinical sequelae for patients.<sup>2</sup> Nonhealing chronic wounds, pressure ulcers, and bed sores can be especially debilitating in the geriatric population.

Our aging population is not the only subject group with issues or concerns about skin health. As the largest and most esthetically important organ in the body, the skin is a growing area of focus for individuals from all age groups. Geriatric people are interested in curbing the effects of age, while younger people are interested in maintaining a youthful, healthy skin condition that will last as long as possible. Rapid and complete healing from all kinds of skin wounds is an essential component of skin health. Therefore, therapies and conventions that target not only healthy but also wounded skin have appealing clinical and quality-of-life benefits.

A central dogma in skin care states that the nutritional supply of oxygen to the skin is delivered through the internal circulation. However, recent data have shown that significant amounts of oxygen may enter via diffusion from the external overlying surface.<sup>3</sup> There is a close dependency between tissue oxygenation and wound healing. Specifically, it has been shown that wounds with <30 mmHg are considered to be hypoxic and have more clinical issues such as being slow to heal, having little or no granulation tissue, and having accumulations of necrotic deposits.<sup>4</sup> In contrast, those wounds with oxygen levels >30 mmHg usually have few longer-term clinical issues and follow a normal course of wound healing.<sup>4</sup>

Maintaining physiologic oxygen levels is critical for normal homeostasis in all tissues. In the skin, white blood cells require oxygen for the respiratory burst mechanism that is necessary for killing ingested bacteria.<sup>5–7</sup> Skin fibroblasts normally secrete a variety of extracellular matrix molecules; this process is critically dependent on physiologic oxygen levels.<sup>8,9</sup> The events of angiogenesis and granulation tissue formation are dependent upon oxygenation.<sup>5,10</sup> Wounds deprived of oxygen deposit collagen poorly and are easily infected. Epithelialization represents a final resolution of the wound, and its mechanisms are optimized at high oxygen levels.<sup>11</sup> As oxygen is essential for wound healing

and there is limited diffusion across the stratum corneum into the epidermis, we wanted to evaluate whether the topical delivery of a total dissolved oxygen in dressing form on intact human subject skin would improve clinical and histologic skin functioning. Biopsy samples were taken from subjects at active and control sites following 8 weeks of treatment. Biopsy samples were coronally sectioned, with one half processed for histopathology to assess impact on hydration, oxidative stress, and structural proteins, and the second half processed for real-time RT-PCR analysis to assess impact on inflammatory markers. Results from these evaluations suggest active mechanisms are in play with the use of topical oxygen therapy to intact, healthy skin. No safety issues were seen in the current study, and structurally significant and biologically relevant differences were detected as a result of 8 weeks of active treatment.

## Materials and methods

### Human subjects

A total of 50 healthy subjects (men and women ages 50–69 years; mean age 58.4) completed a single site, randomized controlled, 8-week study. Subjects had age-appropriate photoaging and stable concomitant medications. Informed consent was obtained from all subjects in the study, which was approved by the Concordia Clinical Research Institutional Review Board, New Jersey.

The semi-occlusive, absorbent, oxygen-enriched dressing (Active Group, OxygeneSys™-Continuous, AcryMed, Inc., Beaverton, OR, USA) was affixed to the skin covering the anterior tibia on one limb, and the contralateral limb was covered with a Kling® bandage (Johnson & Johnson Consumer Products Company, Skillman, NJ, USA) to function as the control. A computer-generated randomization scheme determined which limb (left or right) would receive the experimental dressing. The dressing was wet with an ampule of eye moisturizer and affixed to the shin with a Kling® dressing held together with paper tape. The dressing was applied daily by the subject following bathing and worn for 24 h continuously. The location of the dressing placement was noted by the investigator with black indelible ink. Subjects were permitted to continue using their own skin care, cleansing, and makeup products, but were not allowed to begin any new products for the 8-week duration of the study. No skin care products of any kind were used on the shins where the dressing was applied.

### Clinical measurements

Subjects were evaluated in a blinded fashion by collecting a variety of observations at the designated time points. All study subjects were evaluated by a single investigator. The dressings were removed prior to the blinded clinical investigator's grading. A 5-point ordinal scale was used for all investigator and subject-assessed parameters at baseline, 1 week (compliance check visit), 4 weeks, and 8 weeks, ranging from 0 = no signs or symptoms to 4 = very dramatic signs and symptoms resulting in discomfort, representing an adverse reaction. Investigator-assessed efficacy parameters were as follows: desquamation, roughness, erythema, skin texture, and tolerability parameters were as follows: itching, stinging, and burning. Subject-assessed parameters included: flakiness, roughness, redness, and overall problems. Digital photography of each shin was taken at baseline, 4 and 8 weeks (Fig. 1).

Skin hydration ( $\mu\text{S}$ , micro siemens) was measured with the Dermalab pin probe corneometer (Cortex Technology, Hadsund, Denmark) that used low grade current and conductivity to indirectly measure water content. Transepidermal water loss (TEWL;  $\text{g}/\text{m}^2 \text{ h}$ ) was measured with the Dermalab TransEpidermal Water Loss module (Cortex Technology). Elasticity was measured with the Dermalab skin elasticity module (Cortex Technology, Denmark), and skin coloration was measured with the Dermalab DSM II Colormeter (Cortex Technology). Sensory monofilament test was performed by drawing a cotton fiber over the skin.

### Biopsy

Biopsies were performed in a controlled office environment, 25% humidity, 22°C, during the summer season. Full-thickness biopsies were collected from 12 randomly selected subjects. One 3 mm biopsy was taken from each shin (randomized active and control) at week 8. Biopsies were immediately cut in coronal halves (superficial to deep). One half was immediately placed in ice-cold 2% paraformaldehyde (PFA; Electron Microscopy Sciences, Hatfield, PA, USA) in PBS for histological and immunohistologic analysis and the other half in ice-cold RNAlater (Sigma Chemical Company, St. Louis, MO, USA) for real-time RT-PCR analysis. Histology samples were stored in 2% PFA at 4 °C for 48 h then transferred to 70% ethanol and stored at 4 °C until processed and paraffin embedded. RNAlater samples were stored overnight

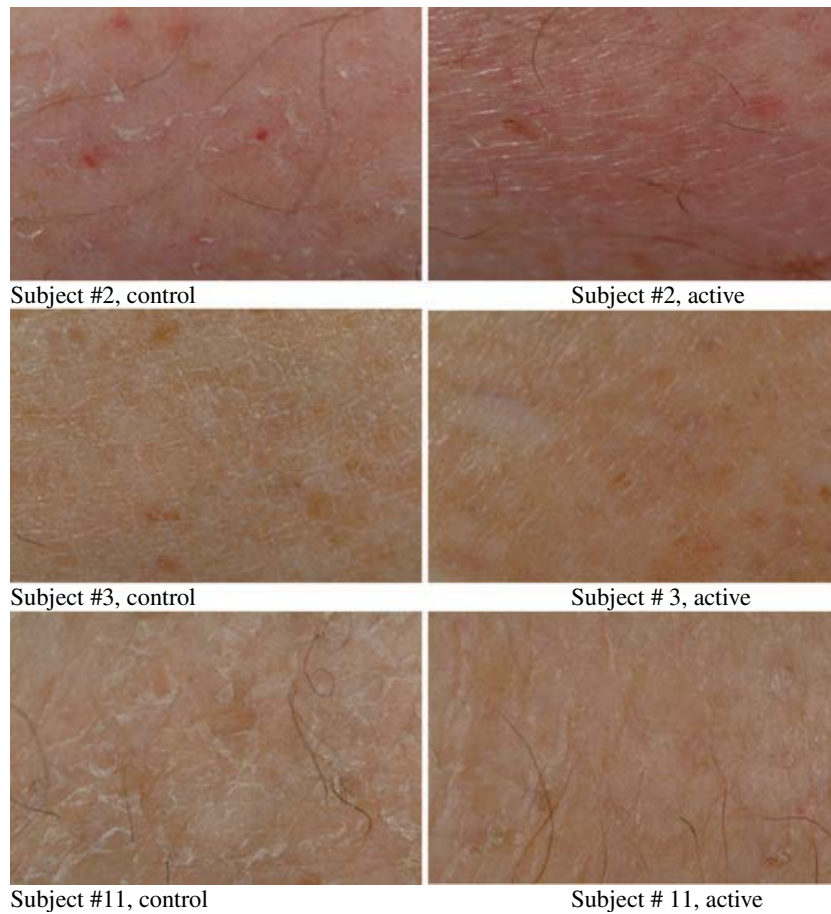
at 4 °C then stored at  $-80$  °C until processed for RNA.

### Histology

All histologic analyses were performed at the 8-week time point, comparing active site to control. Histopathologic evaluations were assessed from paraffin embedded tissues, serially sectioned at 5  $\mu\text{m}$  and stained with hematoxylin and eosin. Immunohistochemistry evaluations were performed by reacting 5  $\mu\text{m}$  sections with the following primary antibodies: oxidative stress DNA adduct 8-hydroxy 2-deoxyguanosine (8-OHdG; Abcam, Cambridge, MA, USA), water-glycerol channel aquaporin-3 (AQP3; Santa Cruz Biotechnology, Santa Cruz, CA, USA), structural proteins filaggrin (Vector Laboratories, Burlingame, CA, USA), collagen I (Abcam), and elastin (Abcam), and processed using standard immunohistochemistry methods. Digital, whole-slide scans (Aperio ScanScope CS; Aperio, Vista, CA, USA) were used for all evaluations to quantify changes in levels, using established digital pathology algorithms. Quantitative assessments on digitally scanned slides have been used to quantify immunohistochemistry in several different tissues.<sup>12</sup> All artifacts were manually excluded prior to digital algorithm. *H*-score, a widely used pathology method for quantitatively evaluating staining features is directly related to staining intensity (0, +1, +2 or +3) of the area, cell or object and calculated by the formula:  $(3 \times \%3+) + (2 \times \%2+) + (1 \times \%1+)$ . Results range from 0 to 300.<sup>13</sup>

### Real-time PCR

Tissues were thawed on ice, then homogenized in RLT lysis buffer (Qiagen, Valencia, CA, USA) using an Omni THq rotor stator (Omni International, Kennesaw, GA, USA) for 30 s per sample. Total RNA was isolated with RNeasy Mini Kit (Qiagen). The cDNA was reverse transcribed with the Superscript III first-strand synthesis system (Invitrogen, Carlsbad, CA, USA). cDNA was diluted 2:1 prior to addition to 10  $\mu\text{L}$  PCRs containing 2 $\times$  Taqman Universal PCR Master Mix (Applied Biosystems, Carlsbad, CA, USA) and amplified on a 7900 Real-Time PCR System (Applied Biosystems). Real-time analysis was performed with the following Taqman probes: IL-6, IL-8, MMP-1 (collagenase), MMP-12 (elastase), TNF- $\alpha$ , TP53, and VEGF and normalized to GAPDH. Samples were analyzed using the  $2^{-\Delta\Delta C_t}$  method, using GAPDH as the housekeeping gene to normalize for sample-to-sample variations in RNA/cDNA. Data are presented as "fold change" in active vs. control.



**Figure 1** Clinical pictures of control vs. active at the 8-week time point.

#### Statistical analysis

A paired Student's *t*-test was performed to determine whether differences existed between the active group vs. the control group. A *P*-value < 0.05 was considered to be statistically significant.

## Results

#### Human subjects

A total of 50 subjects completed the study without any major adverse events or deviations from the study design.

#### Clinical measurements

Skin hydration measurements showed a statistically significant increase in stratum corneum hydration from baseline to 4 weeks, 4–8 weeks, and baseline to 8 weeks (*P* < 0.05 at each time point), with an average increase

in hydration of 41  $\mu$ S in active vs. control from baseline to 8 weeks (Table 1). There were no statistically significant changes in skin coloration with the dermospectrophotometer, nor were there significant changes in TEWL, monofilament sensorial measurement, or elasticity measures across all time points (data not shown).

Blinded clinical investigator-measured outcomes of itching, burning, stinging, and erythema were not significantly different between the active vs. control at all time points compared (data not shown). However, the blinded clinical investigator measures of desquamation, roughness, and skin texture showed significant decreases from baseline to 8-week time points only (*P* < 0.05), see Table 1. There were no significant differences for these measures in active vs. control from baseline to 4 week and 4- to 8-week comparisons. Subject assessment of flakiness, roughness, redness, and overall problems were not significantly different between the active group and the control group at all time points (data not shown).

**Table 1** Clinical measurements between control and treatment sites

		Control	Treatment	<i>P</i> value
Skin hydration ( $\mu$ S)	0–4 weeks	$-8.18 \pm 44.01$	$15.88 \pm 46.17$	0.010
	4–8 weeks	$-2.04 \pm 32.34$	$15.22 \pm 41.96$	0.025
	0–8 weeks	$-10.22 \pm 33.91$	$31.10 \pm 44.71$	<0.001
Desquamation	0–4 weeks	$-0.27 \pm 1.09$	$-0.49 \pm 1.29$	0.356
	0–8 weeks	$-0.12 \pm 0.99$	$-1.08 \pm 1.19$	<0.001
Roughness	0–4 weeks	$-0.33 \pm 1.12$	$-0.53 \pm 1.24$	0.396
	0–8 weeks	$-0.18 \pm 0.99$	$-1.14 \pm 1.15$	<0.001
Skin texture	0–4 weeks	$-0.33 \pm 1.12$	$-0.53 \pm 1.24$	0.396
	0–8 weeks	$-0.18 \pm 0.99$	$-1.14 \pm 1.15$	<0.001

### Histology

Histopathology comparisons between active vs. control sites at the 8-week time point did not reveal any noticeable differences with respect to acanthosis, spongiosis, chronic inflammation, hyperkeratosis, epidermal mononuclear infiltration, focal acantholysis, or dermal edema. Subtle differences exist in epidermal thickness, vascular prominence, and occasional perivascular mononuclear cells. However, these features were concluded to be consistent of normal human skin. No trend change was observable for any of these characteristics between active and control samples. Representative histopathology is shown in Figure 2. Rete peg analysis showed a slightly lower level in active vs. control sites; however, no statistically significant differences were seen.

### Immunohistochemistry

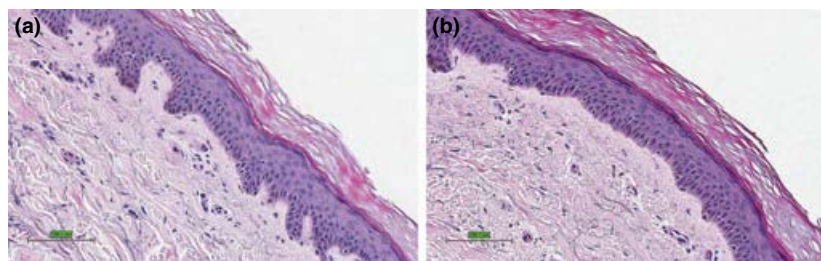
Immunohistochemical (IHC) analysis of coronal, serially sectioned biopsies from the 12 subjects revealed a modest increase in 8-OHdG levels in active vs. control sites, suggesting increased oxygen was penetrating the epidermis through the dressing, resulting in a measurable effect of higher 8-OHdG levels.

The aquaglyceroporin channel, AQP3 showed a slight decrease in active vs. control sites; however,

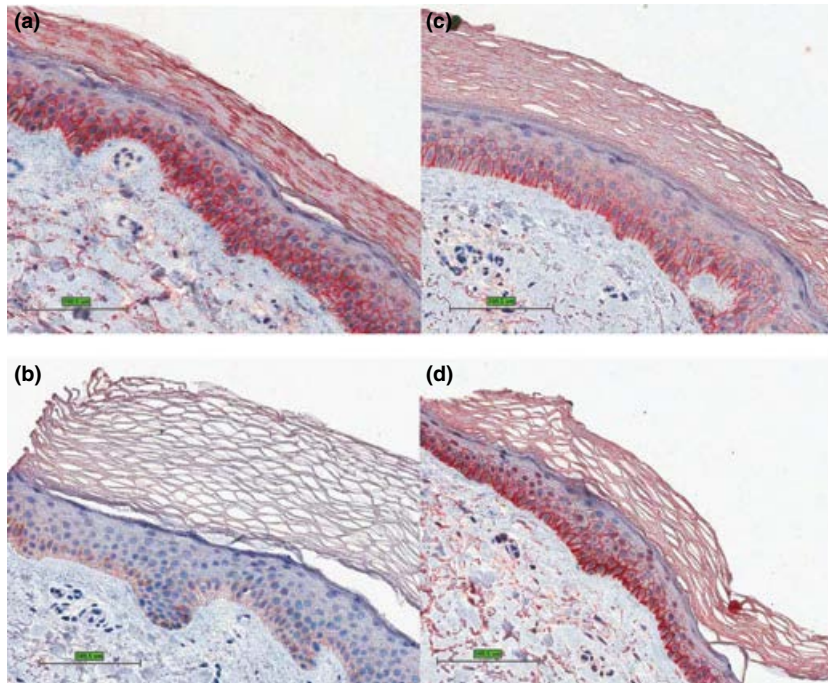
active sites had a more “circumferential” or membrane-localized staining pattern, suggesting recruitment of AQP3 from the cytoplasm to the membrane to facilitate water and glycerol transport (Fig. 3). IHC analysis revealed an increase in *H*-score of filaggrin, collagen I, and elastin proteins in active vs. control sites. The *H*-score value represents a quantitative measurement of staining intensity (quantity of antibody) from whole-slide digital scans of IHC-reacted slides. Evaluated collectively, while not statistically significant, a trend analysis of these key structural proteins demonstrates that these parameters all increase, suggesting a mechanism of influencing structural organization in the skin (Fig. 4 and Table 2).

### Real-time RT-PCR

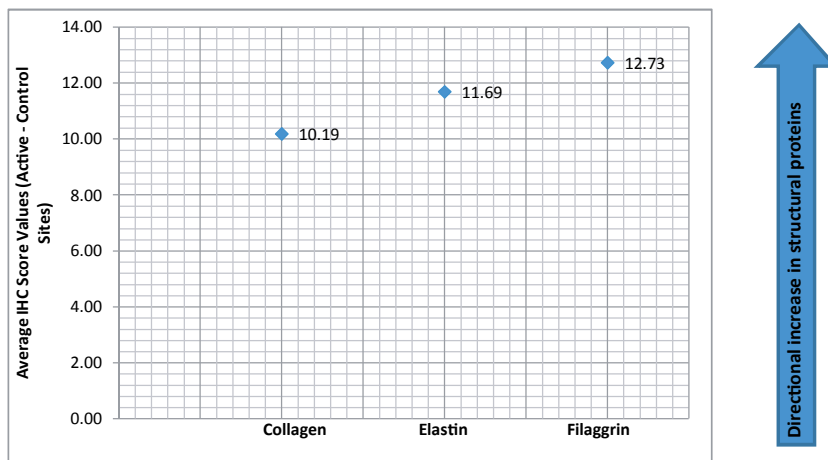
GAPDH was used as the housekeeping gene to normalize for sample-to-sample variations in mRNA. Analysis was performed on a range of inflammatory, structural, angiogenic, and cellular stress genes. Proinflammatory cytokines IL-6, IL-8, and TNF- $\alpha$  showed a modest decrease in active vs. control sites. MMP-1 (collagenase) and MMP-12 (elastase) showed a more robust decrease. During inflammation or damage, both MMP-1 and -12 are up-regulated to degrade extracellular matrix (ECM). Trend analysis of these markers suggests



**Figure 2** Representative histopathology (hematoxylin and eosin stain). (a) Subject #10, control site at the 8-week time point. (b) Subject #10 active site at the 8-week time point. Scale bars = 100  $\mu$ m.



**Figure 3** Representative aquaporin-3 levels at 8 weeks. (a) Subject #10, control site. (c) Subject #10, active site. (b) Subject #13, control site. (d) Subject #13, active site.



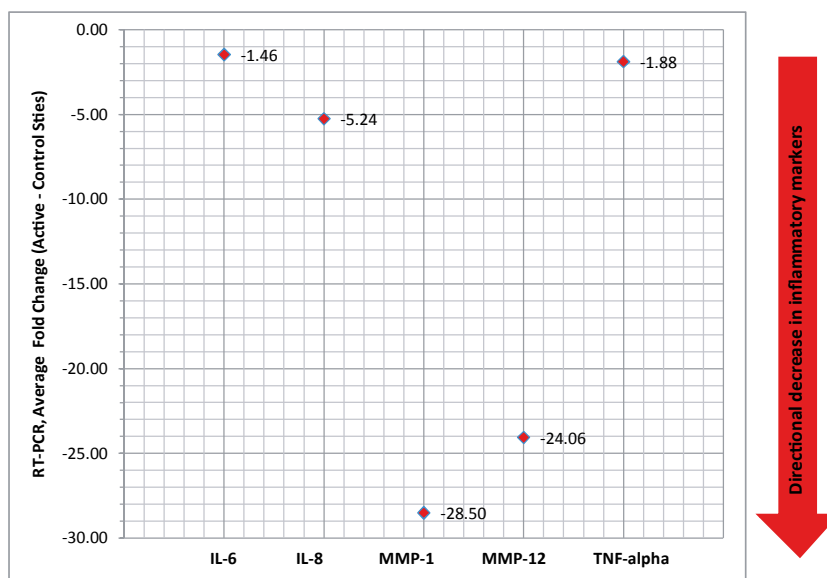
**Figure 4** Immunohistochemistry trend plot of structural proteins collagen I, elastin, and filaggrin at 8 weeks.

consistency in the data and a mechanism of down-regulating the expression of inflammatory markers (Fig. 5 and Table 2). VEGF expression levels were unchanged, suggesting the oxygen dressing neither decreased tissue  $pO_2$  levels to hypoxic levels nor increased  $pO_2$  to hyperoxic levels, both of which would lead to an increase in VEGF expression. TP53 (p53) levels were unchanged. As a central monitor of cellular stress and its environment, including sensing reactive oxygen spe-

cies (ROS) levels, the data suggest the topical oxygen dressing-covered skin was in a healthy state with respect to p53 levels (Table 2).

## Discussion

In the current study, normal, healthy subjects were enrolled in a pilot clinical evaluation to assess the efficacy and tolerability of a dissolved oxygen dressing in



**Figure 5** Real-time RT-PCR trend plot of inflammatory markers at 8 weeks.

improving skin health and appearance. The dressing provides an oxygen-enriched environment that may promote a favorable environment for promotion of healing. Clinical analysis was performed on 50 subjects; histological and gene expression analyses were performed on 12 of the 50 subjects. Clinical data showed the dressing was well tolerated, and several measures of skin health and integrity showed improvement compared with the dressing-only control site. No safety issues were seen during the 8-week period. These data were supported by the immunohistological and gene expression studies, which showed a general reduction in inflammatory response markers and transcription products and a general increase in structural proteins. Additionally, there was a significant decrease in investigator-measured desquamation, roughness, and skin texture in active vs. control sites.

The skin, like all tissues, relies on physiologic levels of oxygen for the maintenance of normal homeostasis. The role of oxygen in maintaining skin homeostasis has been previously described.<sup>14</sup> Numerous homeostatic mechanisms in the skin are dependent on physiologic oxygenation of the skin. When the skin is damaged, wound healing processes are initiated to restore the barrier function, for example, the respiratory burst mechanism leveraged by white blood cells to kill harmful bacteria requires oxygen.<sup>5-7</sup> Additionally, physiologic oxygen levels are needed to enable fibroblasts to perform their normal production of structurally critical extracellular matrix proteins.<sup>5-7</sup> The delivery of topical

dissolved oxygen to the epidermis and potentially the dermis has many implications, including the potential to enhance the wound healing process.<sup>3</sup> While an increase in oxygen is beneficial to the wound healing process, it also increases the amount of ROS-induced physiological changes that may have negative consequences downstream.

Reactive oxygen species are continuously formed in living cells of aerobic organisms as part of normal physiologic processes. Endogenously produced ROS, including H<sub>2</sub>O<sub>2</sub>, superoxide anion radical (O<sub>2</sub><sup>-</sup>), and the hydroxyl radical (\*OH), have many important functions in healthy cells and tissues, acting as secondary messengers in the regulation of cell cycle, proliferation, apoptosis, and response to inflammation or damage.<sup>15</sup> ROS levels are managed by glutathione, glutathione peroxidase, superoxide dismutase, and other scavenging systems.<sup>15</sup> The hydroxyl radical is highly reactive, short-lived and can induce damage to purine and pyrimidine bases and the deoxyribose backbone.<sup>15</sup> The most frequently studied reaction of \*OH with DNA is the formation of 8-OHdG, which when left intact can result in G:C→T:A transversions.

The overall health of the cells and the skin is continually monitored through a complex series of signals, including degree of DNA damage by the level of 8-OHdG. In healthy cells, the cellular repair system, including base excision repair, nucleotide excision repair and mismatch repair, removes the mutations. However, when ROS are produced in amounts that

exceed the cell's capacity to remove the DNA adducts, a series of responses are induced to recruit additional resources to handle the insult. A critical stress response involves phosphorylation and subsequent stabilization of p53 protein, the guardian of the genome, resulting in two major cell pathways – cell cycle arrest for DNA repair, promoting cell survival or apoptosis, eliminating cells that are damaged beyond repair.<sup>16</sup>

In the current study, we observed an increase in 8-OHdG in active vs. control epidermis, suggesting additional oxygen, delivered by the dressing, penetrated the skin and caused an increase in \*OH-intermediates. The DNA analogs appear to be managed by normal physiological processes without deleterious consequences. If the DNA damage were beyond the capacity of the cell to manage, we would anticipate seeing an up-regulation of p53 mRNA expression.

Tumor protein 53 (TP53, p53) is the central monitor of stress in the cell and has been described as the guardian of the genome. p53 has a high turnover rate and is present in cells in low levels in a nonphosphorylated, inactive state. In response to DNA damage, p53 is phosphorylated at multiple sites, along with several feedback loop proteins (ATM, Mdm2, Akt, PTEN), initiating a series of transient p53 pulses. The amount of these p53 pulses ultimately determines cell fate to either cell cycle arrest or apoptosis.<sup>16</sup>

In the current study, p53 expression levels were slightly down-regulated in active treatment sites. This minor change in p53 message expression in active vs. control sites, in combination with the increased production of 8-OHdG indicates that the topical oxygen therapy is penetrating the skin and resulting in positive changes that are not causing excessive stress to the skin. This strongly suggests an active therapy mechanism is in effect without negatively impacting cell and tissue health. Furthermore, VEGF levels were unchanged in active vs. control sites, suggesting the dissolved oxygen dressing created no hypoxic or hyperoxic states.<sup>17</sup> VEGF expression is extremely sensitive to deleterious physiologic changes in oxygen levels. Therefore, as VEGF expression in the current study was unchanged and p53 levels were effectively unchanged, we can conclude that the therapeutic conditions were safe at the cell and tissue level.

Aquaporin-3, the most abundant aquaglyceroporin in the skin, has been shown to transport both water and glycerol.<sup>18</sup> It is primarily found in the stratum basale and stratum spinosum layers of the epidermis and has been identified to play an important role in epidermis and SC hydration, elasticity, wound healing,

**Table 2** Data summary

	Marker	Analysis	Result
Stress monitor	8-OHdG	IHC	Increase
	p53	PCR	No change
	VEGF	PCR	No change
Stratum corneum barrier	AQP-3	IHC	Slight decrease Redistributed to membrane
	Hydration	Clinical	Increase
	Desquamation	Clinical	Decrease
	Roughness	Clinical	Decrease
	Skin texture	Clinical	Decrease
	Inflammation markers	IL-6	PCR
IL-8		PCR	Decrease
TNF- $\alpha$		PCR	Decrease
MMP-1		PCR	Decrease
MMP-12		PCR	Decrease
Epidermis structure		Filaggrin	IHC
	Elastin	IHC	Increase
	Collagen I	IHC	Increase

enhancing keratinocyte proliferation, migration, and differentiation.<sup>18</sup>

Aquaporin-3 levels decreased slightly among subjects in the study. Interestingly, there was an observable change in subcellular distribution of AQP3, shifting from a general cytoplasmic distribution in the control to more of a membrane or circumferential distribution in the active treatment group (Fig. 3). One hypothesis is that active treatment results in a redistribution of AQP3 water channels to the cell membrane to provide a more consistent level of water and glycerol to the epidermis. In the literature, decreased AQP3 levels are associated with dry skin.<sup>18</sup> Additionally, a more cytoplasmic distribution of AQP3 is associated hyperproliferative skin disorders.<sup>18–20</sup> If subjects did not have clinically significant dry skin at the start of the study, we might conclude that either the reduced level of AQP3 channel in active treatment is not of clinical significance or the redistribution of the AQP3 channels counteracts the decrease in AQP3 protein. Alternatively, if a subject had dry skin at the start of the study, the persistent presence of the dissolved oxygen dressing on the active treatment site for 8 weeks could result in reduced evaporation, which could have signaled a reduced need for AQP3 expression or a redistribution to the membrane to further facilitate water and glycerol transport. The redistribution of AQP3 to the membrane and its likely beneficial effect of providing additional water and glycerol to the epidermal layers is supported by clinical data, specifically the statistically significant increase in skin hydration ( $P < 0.001$ ), and



significant decrease in investigator measures of roughness, desquamation, and skin texture, reflecting an increase in moisture in the stratum corneum.

Filaggrin, a structural protein produced in the epidermis by terminally differentiating keratinocytes, facilitates the organization and condensation of keratinocytes and contributes to the formation of the stratum corneum. Filaggrin is synthesized as a proflilaggrin polypeptide, containing 10–12 tandem filaggrin repeats and is stored in intracellular keratohyalin granules in the granular layer of the epidermis. As terminal differentiation continues,  $\text{Ca}^{2+}$  levels increase, which signal the dissolution of the granules and dephosphorylation and cleavage of proflilaggrin into filaggrin monomers. The free filaggrin binds to keratin intermediate filaments, which condense the keratin cytoskeleton, contributing to the cell compaction process that is required for the squamous cell phenotype of the stratum corneum. Filaggrin is further degraded to produce hydrophilic acids, components of natural moisturizing factor, which are significant contributors to hydration and the mildly acidic cutaneous pH.<sup>21</sup> Reductions in proflilaggrin or filaggrin lead to a poorly formed stratum corneum (ichthyosis), which is also prone to water loss (xerosis).<sup>21</sup> Filaggrin levels were higher in active vs. control sites, suggesting treatment increased the production of filaggrin in the skin, potentially contributing to more natural moisturizing factor and a more structurally sound barrier function of the stratum corneum. Additionally, increased filaggrin levels correlate with the increase in investigator-measured skin hydration and decrease in skin texture, roughness, and desquamation. Collagen and elastin, other well-evaluated skin proteins, demonstrated positive changes in active sites in the current study. Collagen I protein levels were slightly higher in active sites vs. control sites. Greater collagen I presence in the dermis may provide skin with greater structural integrity. The consistency in the data lies in the fact that three major structural skin proteins (filaggrin, elastin, and collagen), all increase in their expression in active sites when compared to control sites in the same subject.

Elastin is a structural protein found in the dermis as well as other critical tissues such as blood vessels, heart, bladder, and ligaments where it provides physiologically relevant elasticity. Elastin levels appear to be higher in active vs. control sites. Greater elastin presence in the dermis may provide skin with greater structural integrity and elasticity. Additionally, a trend analysis was conducted on key structural proteins within the skin: collagen, elastin, and filaggrin. Trend analysis of these three proteins suggests consistency in

the data and a mechanism of positively influencing the expression of key structural proteins (Fig. 4). Because these proteins trend together, we can conclude with a higher level of confidence that the active treatment is stimulating beneficial structural changes within the underlying skin.

Inflammatory markers IL-6, IL-8, TNF- $\alpha$ , and the matrix metalloproteinases MMP-1 (collagenase), and MMP-12 (elastase) are up-regulated when inflammatory processes or mechanisms are in play. They are secreted by leukocytes and regulate a wide range of cellular and tissue responses, recruiting macrophages, neutrophils, inducing angiogenesis and inducing remodeling of damaged tissue.<sup>22</sup> In this study, expression of these markers was down-regulated in active vs. control sites, suggesting a decrease in inflammatory pathways or mechanisms and a decrease in breakdown or remodeling of the extracellular matrix within the skin following active treatment.

## Conclusions

The dissolved oxygen dressing was applied to normal, healthy, age-appropriate, photoaged skin and compared with a nontreated site on the contralateral limb in the same subject. The data from this study demonstrate that the total dissolved oxygen dressing has no deleterious effects; rather it stimulates beneficial effects on intact, nonwounded skin.

The increase in 8-OHdG levels in active vs. control sites suggests the dissolved oxygen dressing is increasing  $\text{O}_2$  levels in the skin. The levels of both VEGF and p53 are unchanged, suggesting the increased  $\text{O}_2$  is within acceptable levels within the cells. Decreases in IL-6, IL-8, TNF- $\alpha$ , MMP-1, MMP-12 also suggest insignificant stresses within the cells and skin. The increases in structural proteins collagen I and elastin is likely explained by reduced turnover by a decrease in MMP-1 and MMP-12 mRNA levels (Table 2).

The blinded clinical investigator's measurements of decreased desquamation, roughness, and skin texture in treated vs. control sites correlate with the significant increase in skin hydration. These data are supported histologically by an increase in filaggrin, resulting in increased production of natural moisturizing factor and a redistribution of aquaglyceroporin, AQP3 from the cytoplasm to the membrane.

In summary, the data from this study demonstrate that the dressing has no deleterious effects and appears to stimulate beneficial effects on intact, nonwounded skin.

## References

- 1 Gosain A, DiPietro LA. Aging and wound healing. *World J Surg* 2004; **28**: 321–6.
- 2 Lazarus GS, Cooper DM, Knighton DR *et al*. Definitions and guidelines for assessment of wounds and evaluation of healing. *Arch Dermatol* 1994; **130**: 489–93.
- 3 Roe DF, Gibbons BL, Ladizinsky DA. Topical dissolved oxygen penetrates skin: model and method. *J Surg Res* 2010; **159**: e29–36.
- 4 Heng MC, Harker J, Bardakjian VB, Ayvazian H. Enhanced healing and cost-effectiveness of low-pressure oxygen therapy in healing necrotic wounds: a feasibility study of technology transfer. *Ostomy Wound Manage* 2000; **46**: 52–60.
- 5 Stücker M, Steinbrügge J, Ihrig C *et al*. Rhythmical variations of haemoglobin oxygenation in cutaneous capillaries. *Acta Derm Venereol* 1998; **78**: 408–11.
- 6 Wang W. Oxygen partial pressure in outer layers of skin: simulation using three-dimensional multilayered models. *Microcirculation* 2005; **12**: 195–207.
- 7 Knighton DR, Fylling CP, Fiegel VD, Cerra F. Amputation prevention in an independently reviewed at-risk diabetic population using a comprehensive wound care protocol. *Am J Surg* 1990; **160**: 466–71.
- 8 Hunt TK, Pai MP. The effect of varying ambient oxygen tensions on wound metabolism and collagen synthesis. *Surg Gynecol Obstet* 1972; **135**: 561–7.
- 9 Stücker M, Struk A, Altmeyer P *et al*. The cutaneous uptake of atmospheric oxygen contributes significantly to oxygen supply of human dermis and epidermis. *J Physiol* 2002; **3**: 985–94.
- 10 Medawar PB. The cultivation of adult mammalian skin epithelium in vitro. *Q J Microsc Sci* 1948; **89**: 187–96.
- 11 Cianci P, Hunt TK. Adjunctive hyperbaric oxygen therapy in the treatment of diabetic wounds of the foot. In: Levin, LW O'Neal, JH Bowker, eds. *The Diabetic Foot*, 5th edn. St. Louis, MO: Mosby Year Book; 1993: pp. 305–19.
- 12 Potts SJ, Young GD, Voelker FA. The role and impact of quantitative discovery pathology. *Drug Discov Today* 2010; **15**: 943–50.
- 13 McCarty KS Jr, Miller LS, Cox EB *et al*. Estrogen receptor analysis: correlation of biochemical and immunohistochemical methods using monoclonal antireceptor antibodies. *Arch Pathol Lab Med* 1985; **109**: 716–21.
- 14 Ladizinsky D, Roe D. New insights into oxygen therapy for wound healing. *Wounds* 2010; **22**: 294–300.
- 15 Valko M, Rhodes CJ, Moncol J *et al*. Free radicals, metals and antioxidants in oxidative stress-induced cancer. *Chem Biol Interact* 2006; **160**: 1–40.
- 16 Zhang XP, Liu F, Wang W. Two-phase dynamics of p53 in the DNA damage response. *PNAS* 2011; **108**: 8990–5.
- 17 Sheikh AY, Gibson JJ, Rollins MD *et al*. Effect of hyperoxia on vascular endothelial growth factor levels in a wound model. *Arch Surg* 2000; **135**: 1293–7.
- 18 Hara-Chikuma M, Verkman AS. Roles of aquaporin-3 in the epidermis. *J Invest Dermatol* 2008; **128**: 2145–51.
- 19 Voss KE, Bollag RJ, Fussell N *et al*. Abnormal aquaporin-3 protein expression in hyperproliferative skin disorders. *Arch Dermatol Res* 2011; **303**: 591–600.
- 20 Lee Y, Je YJ, Lee SS *et al*. Changes in transepidermal water loss and skin hydration according to expression of aquaporin-3 in psoriasis. *Ann Dermatol* 2012; **24**: 168–74.
- 21 Sandilands A, Sutherland C, Irvine AD, McLean WH. Filaggrin in the frontline: role in skin barrier function and disease. *J Cell Sci* 2009; **122**: 1285–94.
- 22 Eming SA, Kreig T, Davidson JM. Inflammation in wound repair: molecular and cellular mechanisms. *J Invest Dermatol* 2007; **127**: 514–25.