

available at www.sciencedirect.comjournal homepage: www.europeanurology.com/eufocus

Stone Disease

Could Use of a Flexible and Navigable Suction Ureteral Access Sheath Be a Potential Game-changer in Retrograde Intrarenal Surgery? Outcomes at 30 Days from a Large, Prospective, Multicenter, Real-world Study by the European Association of Urology Urolithiasis Section

Vineet Gauhar^a, Olivier Traxer^b, Daniele Castellani^{c,*}, Christian Sietz^d, Ben Hall Chew^e, Khi Yung Fong^f, Saeed Bin Hamri^g, Mehmet Ilker Gökce^h, Nariman Gadzhievⁱ, Andrea Benedetto Galosi^c, Steffi Kar Kei Yuen^j, Albert El Hajj^k, Raymond Ko^l, Marek Zawadzki^m, Vikram Sridharanⁿ, Mohamed Amine Lakmichi^o, Mariela Corrales^b, Vigen Malkhasyan^p, Deepak Ragoori^q, Boyke Soebhali^r, Karl Tan^s, Chu Ann Chai^t, Azimdjon N. Tursunkulov^u, Yiloren Tanidir^v, Satyendra Persaud^w, Mohamed Elshazly^x, Wissam Kamal^y, Tzevat Tefik^z, Anil Shrestha^{aa}, Heng Chin Tiong^a, Bhaskar Kumar Somani^{bb}

^aDepartment of Urology, Ng Teng Fong General Hospital, Singapore; ^bDepartment of Urology, Sorbonne University, Tenon Hospital, AP-HP, Paris, France; ^cUrology Unit, Azienda Ospedaliero-Universitaria delle Marche, Università Politecnica delle Marche, Ancona, Italy; ^dDepartment of Urology, Medical University of Vienna, Vienna, Austria; ^eDepartment of Urology, University of British Columbia, Vancouver, Canada; ^fYong Loo Lin School of Medicine, National University of Singapore, Singapore; ^gDivision of Urology, Department of Surgery, King Abdullah International Medical Research Center, King Saud Bin Abdulaziz University for Health Sciences, Riyadh, Saudi Arabia; ^hDepartment of Urology, Ankara University School of Medicine, Ankara, Turkey; ⁱDepartment of Urology, St. Petersburg State University Hospital, St. Petersburg, Russia; ^jSH Ho Urology Centre, Department of Surgery, The Chinese University of Hong Kong, Hong Kong, China; ^kDivision of Urology, Department of Surgery, American University of Beirut, Beirut, Lebanon; ^lNepean Urology Research Group, Kingswood, Australia; ^mUrology Unit, St. Anna Hospital, Piaseczno, Poland; ⁿUrology Unit, Sree Paduka Speciality Hospital, Trichy, India; ^oDepartment of Urology, University Hospital Mohammed the VIth of Marrakesh, Marrakesh, Morocco; ^pEndourological Department, A.I. Yevdokimov Moscow State University of Medicine and Dentistry, Moscow, Russia; ^qDepartment of Urology, Asian Institute of Nephrology & Urology, Hyderabad, India; ^rDepartment of Urology, Abdul Wahab Sjahranie Hospital Medical Faculty, Muliawarman University, Samarinda, Indonesia; ^sDepartment of Surgery, Section of Urology, Veterans Memorial Medical Center, Quezon City, Philippines; ^tDepartment of Surgery, Urology Unit, University of Malaya, Kuala Lumpur, Malaysia; ^uUrology Division, AkfaMedline Hospital, Tashkent, Uzbekistan; ^vDepartment of Urology, Marmara University School of Medicine, Istanbul, Turkey; ^wDivision of Clinical Surgical Sciences, University of the West Indies, St. Augustine, Trinidad and Tobago; ^xUrology Unit, Menoufia University, Shibin el Kom, Egypt; ^yUrology Unit, King Fahd General Hospital, Jeddah, Saudi Arabia; ^zDepartment of Urology, Istanbul University Faculty of Medicine, Istanbul, Turkey; ^{aa}Department of Urology, National Academy of Medical Sciences, Bir Hospital, Kathmandu, Nepal; ^{bb}Department of Urology, University Hospitals Southampton, NHS Trust, Southampton, UK

* Corresponding author. Urology Unit, Azienda Ospedaliero-Universitaria delle Marche, Università Politecnica delle Marche, Via Conca 71, 60126 Ancona, Italy. Tel. +39715963571 Fax: +39 7159 63367.

E-mail address: castellanidaniele@gmail.com (D. Castellani).

<https://doi.org/10.1016/j.euf.2024.05.010>

2405-4569/© 2024 The Author(s). Published by Elsevier B.V. on behalf of European Association of Urology. This is an open access article under the CC BY-NC-ND license (<http://creativecommons.org/licenses/by-nc-nd/4.0/>).

Please cite this article as: V. Gauhar, O. Traxer, D. Castellani et al., Could Use of a Flexible and Navigable Suction Ureteral Access Sheath Be a Potential Game-changer in Retrograde Intrarenal Surgery? Outcomes at 30 Days from a Large, Prospective, Multicenter, Real-world Study by the European Association of Urology Urolithiasis Section, *Eur Urol Focus* (2024), <https://doi.org/10.1016/j.euf.2024.05.010>

Article info

Article history:

Accepted May 15, 2024

Associate Editor: Christian Gratzke

Keywords:

Kidney calculi
Flexible ureteroscopy
Lithotripsy
Laser
Retrograde intrarenal surgery
Suction
Vacuum

Abstract

Background and objective: The aim of this study was to evaluate the stone-free status (SFS) rate and complications after flexible ureteroscopy (fURS) for treatment of renal stones using a flexible and navigable suction (FANS) ureteral access sheath.

Methods: Data for adults undergoing fURS in 25 centers worldwide were prospectively collected (August 2023 to January 2024). Exclusion criteria were abnormal renal anatomy and ureteral stones. All patients had computed tomography scans before and within 30 d after fURS with a FANS ureteral access sheath. SFS was defined as follows: grade A, zero fragments; grade B, a single fragment ≤ 2 mm; grade C, a single fragment 2.1–4 mm; and grade D, single/multiple fragments >4 mm. Data for continuous variables are presented as the median and interquartile range (IQR). Multivariable logistic regression was performed to evaluate predictors of grade A SFS.

Key findings and limitations: The study enrolled 394 patients (59.1% male) with a median age of 49 yr (IQR 36–61). The median stone volume was 1260 mm³ (IQR 706–1800). Thulium fiber laser (TFL) was used in 45.9% of cases and holmium laser in the rest. The median lasing time was 18 min (IQR 11–28) and the median operative time was 49 min (IQR 37–70). One patient required a blood transfusion and 3.3% of patients had low-grade fever. No patient developed sepsis. Low-grade ureteral injury occurred in eight patients (2%). The grade A SFS rate was 57.4% and the grade A + B SFS rate was 97.2%, while 2.8% of patients had grade C or D SFS. Eleven patients underwent repeat fURS. Multivariable analysis revealed that a stone volume of 1501–3000 mm³ (odds ratio 0.50) and of >3000 mm³ (odds ratio 0.29) were significantly associated with lower probability of grade A SFS, while TFL use was associated with higher SFS probability (odds ratio 1.83). Limitations include the lack of a comparative group.

Conclusions and clinical implications: fURS using a FANS ureteral access sheath resulted in a high SFS rate with negligible serious adverse event and reintervention rates.

Patient summary: We looked at 30-day results for patients undergoing telescopic laser treatment for kidney stones using a special type of vacuum-assisted sheath to remove stone fragments. We found a high stone-free rate with minimal complications.

© 2024 The Author(s). Published by Elsevier B.V. on behalf of European Association of Urology. This is an open access article under the CC BY-NC-ND license (<http://creativecommons.org/licenses/by-nc-nd/4.0/>).

1. Introduction

Despite continued advances in retrograde intrarenal surgery (RIRS), recent real-world data for 6669 patients in the FLEXOR registry revealed residual fragments in 21.7% of patients, of whom 51.5% required a second intervention [1]. The sepsis rate in the same study was just 1.3%. Hence, there is still much to improve in terms of technical expertise and technology for RIRS. Many aids have been introduced to streamline RIRS and improve procedural success. These include suction via a scope or ureteral access sheath (UAS), postintervention catheters, slimmer single-use scopes, and high-power lasers [2,3]. These improvements have made RIRS a standard of care according to international guidelines [4,5]. It has been reported that vacuum-aided or suction aspiration sheaths have strong potential to improve the stone-free status (SFS) rate and minimize infectious complications associated with the negative effects of high intrarenal pressure and temperature [6]. However, the true potential of the aforementioned advances for RIRS has yet to be investigated. The ideal game-changing technological innovation for RIRS should improve all key outcomes of the procedure, including the rate of immediate single-stage SFS, perioperative and postoperative complications, and the reintervention rate for residual fragments. One recent innovation that has shown much promise is a flexible and navigable sheath (FANS) [7]. We conducted a prospec-

tive, real-world, global study to assess whether FANS could be a potential game-changer for RIRS in adults with renal stones.

2. Patients and methods

2.1. Study protocol

We conducted a prospective, multicenter, investigator-led study as proposed by the ureteroscopy committee of the European Association of Urology Urolithiasis Section. Patients were enrolled between August 1, 2023 and January 10, 2024 by 25 surgeons in 25 centers in 20 countries. Data were gathered after approval from the respective institutional review boards (IRB). Patient consent was obtained for inclusion in an IRB-approved anonymized database (#AINU 12/2022) maintained by the principal investigator (Asian Institute of Nephrology & Urology, Hyderabad, India). Inclusion criteria were patients aged ≥ 18 yr with normal renal anatomy who were undergoing RIRS using FANS for single or multiple renal stones deemed suitable for flexible ureteroscopy (fURS). Only patients for whom a FANS was successfully deployed on first placement were enrolled, regardless of whether they had a preoperative stent or not. All patients underwent a preoperative and at least one postoperative noncontrast computed tomography (CT) scan to assess stone features and residual fragments within 30 d of the index procedure, as described in the study protocol. Children and patients who had abnormal renal anatomy, ureteral stones, or insufficient data records were excluded. As most surgeons were either new users or had limited exposure to FANS use before participation in the study, as well as to standard-

ize the procedure across centers, all surgeons were asked to view a step-by-step video on FANS use [8] and perform a trial of at least one case. Moreover, surgeons were instructed to start suction at the lowest pressure and then sequentially increase the pressure intermittently while ensuring adequate irrigation so that the pelvicalyceal system did not rapidly collapse during suction. Any surgeon who did not feel capable of performing this procedure subsequently left the study.

2.2. Baseline and operative characteristics

Data for baseline and operative characteristics were collected. Stone volume was assessed from CT images by measuring the diameter in three axes and using the ellipsoid formula ($\text{length} \times \text{width} \times \text{depth} \times \pi \times 0.167$). All patients with a positive preoperative culture were treated in accordance with local antibiotic sensitivity. Anticoagulant or antiplatelet use was stopped 3 d before fURS and restarted at the surgeon's discretion. The scope and FANS model and sheath size and the energy source used for lithotripsy depended on local availability and the surgeon's preference. Patients were stented either for symptom relief or as part of staged surgery, and perioperative decisions and postoperative exit strategy were at the surgeon's discretion according to their experience and the resources available. Exit strategies included stent placement, an overnight ureteric catheter, or no drainage tube. Surgeons were asked to grade their experience of FANS use at the end of each case using a 5-point Likert-type scale (1 = excellent; 2 = very good; 3 = good; 4 = average; 5 = difficult). Surgeons were also asked for subjective ratings on whether FANS use had influenced a change in their routine exit strategy. The three FANS models most commonly used (Fig. 1) were ClearPetra (Well Lead Medical, Guangzhou, China), Elephant II (Zhejiang YiGao Medical Technology, Hangzhou, China), and Innovex Medica (Shanghai, China).

2.3. Patient follow-up and study outcomes

Loin pain was assessed on postoperative day 1 and scored using a standard 10-point visual analog scale (VAS), where 0 was the lowest score. All patients were followed for 30 d. Readmissions, reinterventions, and complications reported within 30 d were documented. Longer-term data collection for reinterventions and outcomes is still ongoing. The primary outcome was the SFS rate. SFS was assessed using the bone window for a noncontrast CT scan performed any time within 30 d of RIRS. As there are no standardized grading systems for assessing SFS, we aimed to measure SFS outcomes using the strictest criteria possible and standardized CT imaging in the bone window. The most common threshold for clinically

insignificant residual fragments following RIRS on CT imaging is currently 2 mm [9]. Hence, we used the following grading scheme to optimize our SFS reporting:

- Grade A: 100% stone-free, with zero residual fragments.
- Grade B: a single residual fragment of not more than 2 mm in largest diameter.
- Grade C: a single residual fragment of 2.1–4 mm in largest diameter.
- Grade D: multiple fragments or a single residual fragment of >4 mm in largest diameter.

While there is still debate regarding clinically significant versus insignificant residual fragments, most definitions agree that 2-mm fragments spontaneously pass and that this is an acceptable standard to render patients stone-free [10]. We grouped outcomes into a single-stage SFS category that included grades A and B (as these patients were not candidates for reintervention according to repeat CT imaging), and a non-stone-free category that included grades C and D (patients with an indication for reintervention). This categorization helps in simplifying the reintervention strategy.

Any patient for whom reintervention was planned within 30 d underwent a repeat noncontrast CT scan 1–2 d before the reintervention to reassess their residual fragment status. The modality planned for the reintervention was also documented. Other secondary outcomes measured within 30 d of the index procedure were intraoperative and postoperative complications, including bleeding, transfusion, ureteric injury, pelvicalyceal system injury, infectious complications, persistent hematuria, and sepsis, defined according to the Third International Consensus (Sepsis-3) [11]. These outcomes were analyzed to investigate whether FANS can improve the single-stage SFS rate and minimize repeat interventions.

2.4. Statistical analysis

Results are reported as the median and interquartile range (IQR) for continuous variables, and as the frequency and proportion for categorical variables. Variables included in multivariable analysis models were predetermined on the basis of results in the literature. A priori multivariable logistic regression analysis was performed to identify predictors of 100% SFS (grade A), with odds ratio (OR) and 95% confidence interval (CI) results reported. Statistical significance was set at $p < 0.05$. All statistical analyses were performed using R version 4.1.2 (R Foundation for Statistical Computing, Vienna, Austria).

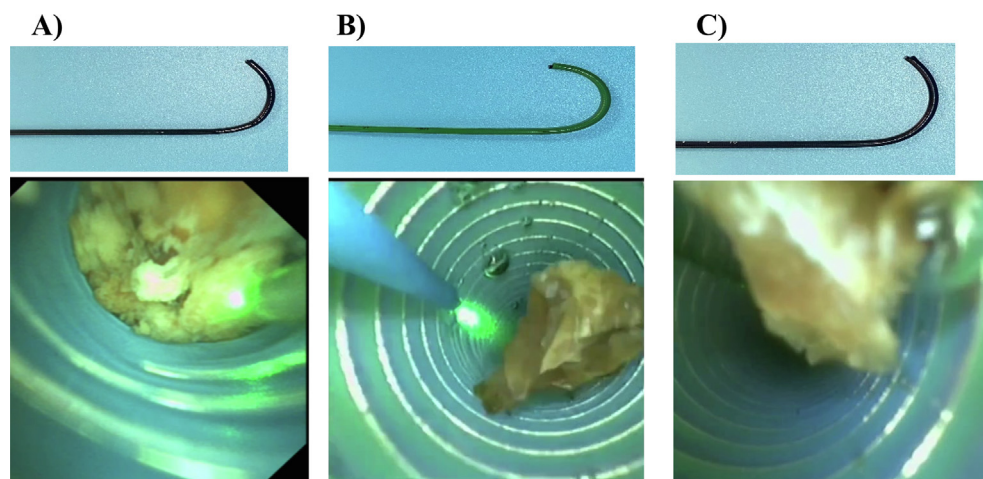


Fig. 1 – External and internal views of the ureteral access sheaths used: (A) Elephant, (B) ClearPetra, and (C) Innovex.

3. Results

Data for 420 patients were collected. Of these, 26 patients were excluded because they did not report back in time for a CT scan because of regional constraints, leaving 394 patients for analysis. **Table 1** shows the patient characteristics at baseline. The median age was 49 yr. 59.1% were male, and 69% were first-time stone formers. The most common symptom at presentation and indication for intervention was pain (80.7% of cases). Only 9.9% of patients underwent surgery for incidental stones. Some 19% of patients had a positive preoperative urine culture and 93% received a single dose of antibiotics at induction. Preoperative stenting was performed in 58.6% of the patients, which was part of an elective staged RIRS in 84 cases (21.3%). The most prevalent stone diameter category was 1.1–2 cm (58.6%), followed by <1 cm (24.1%) and >2 cm (17.3%). Some 64.2% of patients had a stone volume of <1500 mm³. Stone location was the interpolar region or renal pelvis in 37.6% of cases, and the lower pole in 32.0%.

Procedures were preferentially performed under general anesthesia (**Table 2**). A 10/12 Fr sheath was the size most commonly used (41.6%) and a single-use or disposable scope was preferentially used (89.3% of cases). Tulumium fiber laser (TFL) was used in 45.9% of cases and holmium laser (30–100 W) was used in the remainder. The median laser time (recorded on the machine) was 18 min and the median URS time (actual time for which the scope was used) was 35 min. The median total operative time (from UAS insertion to the exit strategy) was 49 min. The most

Table 1 – Patient characteristics at baseline (n = 394)

Parameter	Result
Median age, yr (interquartile range)	49 (36–61)
Male, n (%)	233 (59.1)
American Society of Anesthesiologists score, n (%)	
1	222 (56.3)
2	139 (35.3)
3	33 (8.4)
Median body mass index, kg/m ² (interquartile range)	26 (24–29)
Anticoagulant/antiplatelet use, n (%)	45 (11.4)
First-time stone former, n (%)	272 (69.0)
Presentation, n (%)	
Hematuria	34 (8.6)
Pain	318 (80.7)
Fever	11 (2.8)
Incidental	39 (9.9)
Preoperative positive urine culture, n (%)	75 (19.0)
Antibiotic prophylaxis, n (%)	327 (83.0)
Prestented (any reason), n (%)	231 (58.6)
Elective presentation for staged surgery, n (%)	84 (21.3)
Right-sided kidney, n (%)	166 (42.1)
Largest stone diameter, n (%)	
<1 cm	95 (24.1)
1.1–2 cm	231 (58.6)
>2 cm	68 (17.3)
Median Hounsfield units (interquartile range)	1085 (890–1225)
Median stone volume, mm ³ (interquartile range)	1260 (706–1800)
Stone volume category, n (%)	
≤1500 mm ³	253 (64.2)
1501–3000 mm ³	98 (24.9)
>3000 mm ³	43 (10.9)
Stone location, n (%)	
Multiple locations	25 (6.3)
Upper pole only	95 (24.1)
Renal pelvis/interpolar region	148 (37.6)
Lower pole only	126 (32)

Table 2 – Operative characteristics for the 394 patients

Parameter	Result
General anesthesia, n (%)	324 (83.2)
Sheath size, n (%)	
12–14 Fr	83 (21.1)
11–13 Fr	147 (37.3)
10–12 Fr	164 (41.6)
Sheath brand, n (%)	
ClearPetra	244 (61.9)
Innovex	25 (6.3)
Elephant	94 (23.9)
Other	31 (7.9)
Disposable scope, n (%)	352 (89.3)
Scope tip size ≥8 Fr, n (%)	173 (43.9)
Tulumium fiber laser, n (%)	181 (45.9)
Median laser time, min (interquartile range)	18 (11–28)
Median ureteroscopy time, min (interquartile range)	35 (25–55)
Median total operative time, min (interquartile range)	49 (37–70)
Stone lithotripsy technique, n (%)	
Dusting with suction evacuation	155 (39.3)
Popcorn mode with suction evacuation	16 (4.1)
Fragment evacuation using suction	223 (56.6)
Basket use for repositioning or extraction, n (%)	52 (13.2)
Need for a sheath change because of malfunction, n (%)	8 (2.0)
Sheath able to access all parts of the kidney, n (%)	342 (86.8)
Suction working effectively, n (%)	381 (96.7)
Postoperative exit strategy, n (%)	
Double J stent	311 (78.9)
Overnight ureteric catheter	56 (14.2)
No stent or ureteric catheter (totally tubeless)	27 (6.9)
Median Likert-scale rating for UAS performance (interquartile range)	
Ease of suction	2 (1–2)
Manipulation	2 (1–2)
Visibility	1 (1–3)

UAS = ureteral access sheath.
^aSignificant *p* values are in bold font.

common lithotripsy strategy was fragmentation and suction evacuation (54.8%), followed by pure dusting and suction (39.3%). A basket was used for either repositioning or fragment extraction in only 13.2% of cases. In eight patients, a sheath malfunction requiring a change of sheath occurred. In five of these cases, this occurred at the end of the procedure, when the surgeon fired the laser onto the sheath during suction/extraction of a trapped stone, which created a hole and led to suction failure. For the other three cases, no reason was given.

The median Likert-scale score for sheath performance was 2 (IQR 1–2) for ease of suction, 2 (IQR 1–2) for manipulation, and 1 (IQR 1–3) for visibility. Overall, a suction mechanism that worked well was reported for 96.7% of cases, and access to all parts of the kidney with the FANS for 86.8% of cases. Among kidneys for which FANS did not reach all parts of the collecting system, a reusable scope was employed in 82.1%. The exit strategy was a double-J stent in 78.9%, an overnight ureteric catheter in 14.2%, and no drainage tube in 6.9% of cases.

Table 3 reports intraoperative and postoperative outcomes. In 6.1% of cases, there was mild oozing caused by scope movement in the collecting system, but this did not hamper the surgery. One patient experienced intraoperative bleeding requiring transfusion in the immediate postoperative period. No embolization was needed. None of the cases reported persistent hematuria beyond 24 h. Some 3.3% of patients had low-grade fever (defined as <37.5 °C; Clavien grade 2), with no cases of sepsis reported. The median VAS pain score was 1 (IQR 1–2). The median hospital stay

Table 3 – Intraoperative and postoperative complications for the 394 patients

Parameter	Result
Intraoperative bleeding caused by the sheath/suction but not obscuring surgery, <i>n</i> (%)	24 (6.1)
Case abandoned for any reason (<i>n</i>)	0
Intraoperative bleeding requiring a transfusion, <i>n</i> (%)	1 (0.3)
Cases with ureteric injury managed with stenting alone, <i>n</i> (%)	8 (2.0)
Pelvic-ureteral junction	2 (0.5)
Proximal ureter	2 (0.5)
Mid ureter	2 (0.5)
Distal ureter	2 (0.5)
Traxer grade of ureteric injury cases managed with stenting alone, <i>n</i> (%)	
Grade 1	7 (1.8)
Grade 2	1 (0.3)
Ureteral injury in nonprestedented patients, <i>n/N</i> (%)	5/163 (3)
Pelvic-ureteral abrasion due to sheath movement, with no contrast extravasation, <i>n</i> (%)	5 (1.3)
Perinephric stranding on the first CT scan but not requiring intervention, <i>n</i> (%)	28 (7.1)
Fever within first 24 h, <i>n</i> (%)	12 (3.3)
Sepsis (<i>n</i>)	0
Persistent hematuria beyond 24 h (<i>n</i>)	0
Median loin pain score on postoperative day 1 (interquartile range)	1 (1–2)
Median length of hospital stay, d (interquartile range)	1 (0–2)
Readmission within 30 d, <i>n</i> (%)	6 (1.5)

CT = computed tomography.

was 1 d. For eight patients (2%), a ureteral mucosal injury with no contrast extravasation on a retrograde pyelogram was identified on careful inspection after sheath removal. All of these cases were managed via stenting alone. Six patients required readmission for any reported complication within 30 d: five patients had stent symptoms (Clavien grade 1) and one patient had a fungal urinary infection (Clavien grade 2).

SFS results are reported in [Supplementary Table 1](#). According to visual intraoperative inspection, grade A SFS was observed in 51.3% of cases. However, actual residual fragment assessment on CT identified grade A SFS in 57.4%, grade B in 39.8%, grade C in 2.0%, and grade D in 0.8% of patients. A second intervention was initially planned for 17 patients with residual fragments, but after a repeat CT scan, only 11 underwent repeat RIRS within 30 d. Multivariable analysis ([Table 4](#)) revealed that stone volumes of 1501–3000 mm³ (OR 0.50, 95% CI 0.30–0.82; *p* < 0.01) and >3000 mm³ (OR 0.29, 95% CI 0.13–0.62; *p* < 0.01) were significantly associated with lower probability of grade A SFS, while TFL use was associated with higher probability (OR 1.83, 95% CI 1.16–2.92; *p* = 0.01) of grade A SFS.

4. Discussion

While urologists have tried to standardize RIRS steps, real-world studies show that fURS is in a transformative stage because of technological innovations [1], such as the use of suction [3] and more recently the use of FANS [7]. Even though these options did improve surgical efficiency and minimized complications [12], the limitation of earlier suction UAS models was a failure to achieve zero residual fragments because of an inability to aspirate dust, debris, and

Table 4 – Multivariable logistic regression analysis of parameters associated with 100% stone-free status at 30 d

	OR (95% CI)	<i>p</i> value ^a
Stone volume (reference: ≤1500 mm ³)		
1501–3000 mm ³	0.50 (0.30–0.82)	<0.01
>3000 mm ³	0.29 (0.13–0.62)	<0.01
Stone location (reference: multiple locations)		
Upper pole	1.53 (0.59–4.00)	0.38
Renal pelvis/interpolar region	0.99 (0.40–2.47)	0.98
Lower pole	0.98 (0.39–2.45)	0.96
Hounsfield units	1.000 (0.99–1.01)	0.819
Use of thulium fiber laser (reference: holmium laser)	1.83 (1.16–2.92)	0.01
Total operative time	0.99 (0.99–1.01)	0.19
Stone fragmentation (reference: dusting only)		
Popcorn mode only	2.26 (0.70–8.25)	0.19
Fragmentation and suction evacuation	0.75 (0.47–1.21)	0.24

^a Significant *p* values are in bold font.

fragments that settle in dependent calyces, especially in the lower pole. This is probably why Zhang et al [13] concluded from their retrospective study that a flexible suction UAS achieved a higher immediate SFS rate and could further improve RIRS outcomes.

To the best of our knowledge, this is the first global, prospective, multicenter, real-world study to investigate whether the ability to deploy a scope and steer the flexible tip into different parts of the kidney and to use suction aspiration makes FANS a potential game-changer by improving all key outcomes for RIRS. We focused on the probability of achieving grade A SFS with negligible complication and reintervention rates.

FANS were safely deployed and used in all 394 cases. While no major reported issues with the suction or aspiration mechanism were reported, sheath malfunction requiring replacement occurred in 2% of cases, but this was not associated with any particular FANS model. In 86.8% of cases, the surgeon was able to navigate the sheath to all parts of the kidney. We could not assess why this was not possible in all cases, but this was only observed for the 12/14 Fr UAS size. Similar findings were reported by Gauhar et al [7] for their analysis of 10/12 and 12/14 Fr sheaths from a single company, and by Liang et al [14]. Both studies identified steep infundibulum-pelvic angles as a key limitation for large-diameter sheaths. Liang et al also mentioned that this may hamper the ability to remove all fragments, and baskets could still be needed for stone repositioning, which is perhaps why baskets were used to either reposition or extract fragments in 13.2% of our cases. Mechanical factors such as the use of reusable scopes, whose deflection is perhaps compromised by wear and tear, as well as surgeon preference, may have played a role in the use of baskets. Against this background and taking into

consideration the maximum performance achieved with a fresh scope, surgeons in our study preferentially chose to use disposable scopes. Whether FANS use can minimize or completely obviate the need for baskets is an issue for further research. However, the rate of basket use in our study was much lower than rates reported for use of a traditional UAS [1].

The goal driving innovation and the use of better technology in RIRS is further improvement in the single-stage SFS rate [14,15]. Apart from technical developments to minimize residual fragments, an equally important issue is the application of strict criteria to identify and categorize fragments. Hence, we used residual fragment categories for our reporting. Our grade A SFS rate (single intervention within 30 d) was 57.4%. Our overall single-stage grade A + B SFS rate of 97.2% demonstrates how a technique and technology when used well can yield good results in this setting, despite the large stone volumes in our series. To mitigate the need for reintervention because of overestimation of the residual fragment burden on CT [16], we performed a second CT scan in 17 patients for whom reintervention within 30 d was planned to justify the need for an endourological reintervention and to counsel patients accordingly. Eventually, 11 RIRS reinterventions were performed, as the literature indicates that fragments >4 mm only have a 9% chance of spontaneous expulsion and are associated with significantly higher odds of further stone events or reinterventions over 1-yr follow-up [10]. Thus, our 30-day reintervention rate was just 2.8%, which is significantly lower than in previous studies. Guideline suggestions that later imaging, preferably after 6 wk, is a better point at which to estimate the true fragment burden in patients for whom 100% on-table clearance was uncertain [4,5] and could avoid unnecessary repeat imaging. The ability to visually inspect and simultaneously remove fragments meant that surgeons in our study were confident of achieving on-table zero fragments in 56.1% of cases, which corresponded to the postoperative CT findings. Good use of technology and appropriate imaging techniques can improve surgeon confidence in realistically counseling patients on expected outcomes in the immediate postoperative period, convincing them to adopt a wait-and-see strategy to avoid hurried interventions in real-world practice [17]. Importantly, our results were achieved despite cases with stones >2 cm (17.3%), stone volumes >3000 cm³ (10.9%), lower-pole stones (32%), and stones in multiple locations (6.3%). While RIRS is safe in such cases, these factors can potentially contribute to a lower single-stage SFS rate following RIRS [18,19]; further studies are needed to understand the nuances of FANS use in these cases. While we did have a high SFS rate, it is important to consider that this was a prospective study performed in a real-world setting. Thus, failure to access the collecting system in 13.2% of cases could also be attributed to suboptimal mechanical ability of reusable scopes, whereby wear and tear might have affected their deflection. Use of a disposable scope for all cases might be a solution to overcome this issue.

Interestingly, our regression analysis revealed that TFL use was significantly associated with higher odds of achiev-

ing zero fragments. Other studies identified TFL as a better laser for RIRS, as demonstrated by a recent meta-analysis [20]. However, successful SFS may be attributed to the surgeon rather than to the laser modality, and TFL is not available in all centers. Another interesting point is that surgeons preferred fragmentation or dusting as a lithotripsy strategy over the popcorn mode, and were able to achieve high SFS rates by carefully deploying active suction-aspiration to remove dust and fragments. This was done within short operative times and a minimal lasering time, with a median of just 18 min. Our lasering time and efficiency seem better than those reported for traditional non-suction RIRS [1]. As fragments can be easily evacuated in real time during laser lithotripsy, when its global use increases, further studies could assess if laser type and power remain predictors of RIRS outcomes.

Even though many surgeons in our study were either new users or had limited exposure to FANS use, we observed a good safety profile. The ability of FANS to reduce intrarenal pressure over conventional suction [21] definitely contributed to our very low rate of infectious complications. There were no cases of sepsis in our study and only 3.3% of patients had low-grade fever, which resolved within 24 h. Patients showed good tolerance to FANS use, and almost all patients were discharged in 24 h. The low median VAS score for loin pain reported by patients on postoperative day 1 is in line with other studies [14,15]. Studies using vacuum-assisted UAS have shown that the absence of intravasation due to intermittent suction/aspiration prevents overstretching of the collecting system and minimizes postoperative inflammatory changes and postoperative loin pain [7,22]. Active movement of the sheath into different parts of the collecting system did lead to some oozing, but this did not hinder the surgery, as any blood can be easily aspirated to maintain clear vision. However, this movement could have been responsible for the mucosal abrasion noted on final inspection in five cases, but there was no extravasation of contrast suggestive of perforation. For all five patients, a stent was inserted as a precaution. Of the eight patients who had a ureteric injury, five did not have a preoperative stent and were managed postoperatively with just double-J stenting. An incorrect insertion technique and a large UAS size in patients without a preoperative stent have been identified as risk factors for UAS ureteral injury, and all necessary precautions should be taken to mitigate this complication [23]. There were no ureteric avulsions and only one patient needed a transfusion because of bleeding. The 30-d readmission rate was low at 1.5%, and the readmissions were mainly for stent symptoms. Stents are a boon and bane to urologists and patients alike. While unavoidable in certain circumstances, they must be used judiciously, as they cause stent symptoms that defeat good fURS outcomes [24]. In our study, management involved an overnight ureteric catheter in 14.25% of patients and a stent was completely avoided in 6.9%. This suggests that if used properly, FANS is not only safe and effective but can facilitate visual inspection to ensure complete fragment removal and the absence of injury. Thus, FANS use could enhance the RIRS experience for patients by mitigating stent placement

and consequent problems. While not assessed here, future studies could investigate whether FANS use can improve quality of life for patients undergoing RIRS.

If a technique or technological innovation significantly helps in changing the way a surgical procedure is performed, it may be a potential game-changer; if it becomes a measure of excellence that can be universally replicated, it may become a gold standard [25]. Our global study supports the prediction by Schoenthaler et al [26] that use of the newest generation of advanced technical equipment—FANS, in our case—and a CT protocol as the benchmark for evaluation of stone fragments can result in a very high SFS rate and low reintervention rates without compromising RIRS safety, as clearly reflected in our results.

Our study limitations include a patient population without anatomic anomalies, no comparator group, and lack of assessment of the direct impact on costs and patient quality of life. Nevertheless, our results show that FANS use is safe and efficacious, with acceptable surgical morbidity and no serious adverse events. Importantly, the complication and reintervention rates were significantly lower than those in previous studies using conventional UAS [27].

5. Conclusions

A FANS can help in achieving zero residual fragment status if used judiciously. It is possible to achieve a very high single-stage SFS rate with negligible serious adverse event and reintervention rates for stones in all locations. We feel that the combination of suction and a FANS could pave the way to improving and changing the way in which RIRS will be performed in the future.

Author contributions: Daniele Castellani had full access to all the data in the study and takes responsibility for the integrity of the data and the accuracy of the data analysis.

Study concept and design: Gauhar, Chew, Traxer, Seitz, Somani, Castellani.
Acquisition of data: Bin Hamri, Gökce, Gadzhiev, Castellani, Yuen, El Hajj, Ko, Zawadzki, Sridharan, Lakmichi, Corrales, Malkhasyan, Ragoori, Soebhali, Tan, Chai, Tursunkulov, Tanidir, Persaud, Elshazly, Kamal, Tefik, Shrestha, Fong, Gauhar.

Analysis and interpretation of data: Gauhar, Castellani, Chew, Traxer, Seitz, Somani, Tiong.

Drafting of the manuscript: Gauhar, Castellani.

Critical revision of the manuscript for important intellectual content: Chew, Traxer, Seitz, Somani, Castellani, Galosi.

Statistical analysis: Fong.

Obtaining funding: None.

Administrative, technical, or material support: None.

Supervision: Traxer, Somani.

Other: None.

Financial disclosures: Daniele Castellani certifies that all conflicts of interest, including specific financial interests and relationships and affiliations relevant to the subject matter or materials discussed in the manuscript (eg, employment/affiliation, grants or funding, consultancies, honoraria, stock ownership or options, expert testimony, royalties, or patents filed, received, or pending), are the following: Mehmet Ilker Gökce is a lecturer for Cook Medical and a Delphi panel meeting mem-

ber/consultant for Boston Scientific. Ben Hall Chew is a consultant for Boston Scientific and The Ureteral Stent Company. The remaining authors have nothing to disclose.

Funding/Support and role of the sponsor: None.

Appendix A. Supplementary data

Supplementary data to this article can be found online at <https://doi.org/10.1016/j.euf.2024.05.010>.

References

- [1] Gauhar V, Chew BH, Traxer O, et al. Indications, preferences, global practice patterns and outcomes in retrograde intrarenal surgery (RIRS) for renal stones in adults: results from a multicenter database of 6669 patients of the global FLEXible Ureteroscopy Outcomes Registry (FLEXOR). *World J Urol* 2023;41:567–74. <https://doi.org/10.1007/s00345-022-04257-z>.
- [2] Castellani D, Fong KY, Lim EJ, et al. Comparison between holmium: YAG laser with MOSES technology vs thulium fiber laser lithotripsy in retrograde intrarenal surgery for kidney stones in adults: a propensity score-matched analysis from the FLEXible ureteroscopy outcomes registry. *J Urol* 2023;210:323–30. <https://doi.org/10.1097/JU.0000000000003504>.
- [3] Giullioni C, Castellani D, Traxer O, et al. Experimental and clinical applications and outcomes of using different forms of suction in retrograde intrarenal surgery. Results from a systematic review. *Actas Urol Esp* 2024;48:57–70. <https://doi.org/10.1016/j.acuroe.2023.06.001>.
- [4] Assimos D, Krambeck A, Miller NL, et al. Surgical management of stones: American Urological Association/Endourological Society guideline, part II. *J Urol* 2016;196:1161–9. <https://doi.org/10.1016/j.juro.2016.05.091>.
- [5] Skolarikos A, Jung H, Neisius A, et al. EAU guidelines on urolithiasis. Arnhem, The Netherlands: European Association of Urology; 2023. <https://d56bochluxqz.cloudfront.net/documents/full-guideline/EAU-Guidelines-on-Urolithiasis-2023.pdf>.
- [6] Pauchard F, Ventimiglia E, Corrales M, Traxer O. A practical guide for intra-renal temperature and pressure management during RIRS: what is the evidence telling us. *J Clin Med* 2022;11:3429. <https://doi.org/10.3390/jcm11123429>.
- [7] Gauhar V, Traxer O, Castellani D, et al. A feasibility study on clinical utility, efficacy and limitations of two types of flexible and navigable suction ureteral access sheaths in retrograde intrarenal surgery for renal stones. *Urology* 2023;78:173–9. <https://doi.org/10.1016/j.urol.2023.05.032>.
- [8] Gauhar V, Ong CSH, Traxer O, et al. Step-by-step guide to flexible and navigable suction ureteric access sheath (FANS). *Urol Video J* 2023;20:100250. <https://doi.org/10.1016/j.urolvj.2023.100250>.
- [9] Ghani KR, Wolf JSJ. What is the stone-free rate following flexible ureteroscopy for kidney stones? *Nat Rev Urol* 2015;12:281–8. <https://doi.org/10.1038/nrurol.2015.74>.
- [10] Brain E, Geraghty RM, Lovegrove CE, Yang B, Somani BK. Natural history of post-treatment kidney stone fragments: a systematic review and meta-analysis. *J Urol* 2021;206:526–38. <https://doi.org/10.1097/JU.0000000000001836>.
- [11] Singer M, Deutschman CS, Seymour C, et al. The third international consensus definitions for sepsis and septic shock (Sepsis-3). *JAMA* 2016;315:801–10. <https://doi.org/10.1001/jama.2016.0287>.
- [12] Jahrreiss V, Nedbal C, Castellani D, et al. Is suction the future of endourology? Overview from EAU Section of Urolithiasis. *Ther Adv Urol* 2024;16:17562872241232276. <https://doi.org/10.1177/17562872241232275>.
- [13] Zhang Z, Xie T, Li F, et al. Comparison of traditional and novel tip-flexible suctioning ureteral access sheath combined with flexible ureteroscope to treat unilateral renal calculi. *World J Urol* 2023;41:3619–27. <https://doi.org/10.1007/s00345-023-04648-w>.
- [14] Liang H, Liang L, Lin Y, et al. Application of tip-bendable ureteral access sheath in flexible ureteroscopic lithotripsy: an initial experience of 224 cases. *BMC Urol* 2023;23:175. <https://doi.org/10.1186/s12894-023-01347-x>.

- [15] Gauhar V, Somani BK, Heng CT, et al. Technique, feasibility, utility, limitations, and future perspectives of a new technique of applying direct in-scope suction to improve outcomes of retrograde intrarenal surgery for stones. *J Clin Med* 2022;11:5710. <https://doi.org/10.3390/jcm11195710>.
- [16] Gauhar V, Castellani D, Chew BH, et al. Does unenhanced computerized tomography as imaging standard post-retrograde intrarenal surgery paradoxically reduce stone-free rate and increase additional treatment for residual fragments? Outcomes from 5395 patients in the FLEXOR study by the TOWER group. *Ther Adv Urol* 2023;15:17562872231198628. <https://doi.org/10.1177/17562872231198629>.
- [17] Rippel CA, Nikkel L, Lin YK, et al. Residual fragments following ureteroscopic lithotripsy: incidence and predictors on postoperative computerized tomography. *J Urol* 2012;188:2246–51. <https://doi.org/10.1016/j.juro.2012.08.040>.
- [18] Giuliani C, Castellani D, Somani BK, et al. The efficacy of retrograde intra-renal surgery (RIRS) for lower pole stones: results from 2946 patients. *World J Urol* 2023;41:1407–13.
- [19] Breda A, Angerri O. Retrograde intrarenal surgery for kidney stones larger than 2.5 cm. *Curr Opin Urol* 2014;24:179–83. <https://doi.org/10.1097/MOU.000000000000030>.
- [20] Uleri A, Farré A, Izquierdo P, et al. Thulium fiber laser versus holmium:yttrium aluminum garnet for lithotripsy: a systematic review and meta-analysis. *Eur Urol* 2024;86:529–540. <https://doi.org/10.1016/j.eururo.2024.01.011>.
- [21] Chen Y, Li C, Gao L, et al. Novel flexible vacuum-assisted ureteral access sheath can actively control intrarenal pressure and obtain a complete stone-free status. *J Endourol* 2022;36:1143–8. <https://doi.org/10.1089/end.2022.0004>.
- [22] Lai D, He Y, Li X, Chen M, Zeng X. RIRS with vacuum-assisted ureteral access sheath versus MPCNL for the treatment of 2–4 cm renal stone. *Biomed Res Int* 2020;2020:8052013. <https://doi.org/10.1155/2020/8052013>.
- [23] Aykanat C, Balci M, Senel C, et al. The impact of ureteral access sheath size on perioperative parameters and postoperative ureteral stricture in retrograde intrarenal surgery. *J Endourol* 2022;36:1013–7. <https://doi.org/10.1089/end.2021.0751>.
- [24] Muslumanoglu AY, Fuglsig S, Frattini A, et al. Risks and benefits of postoperative double-J stent placement after ureteroscopy: results from the Clinical Research Office of Endourological Society Ureteroscopy Global Study. *J Endourol* 2017;31:446–51. <https://doi.org/10.1089/end.2016.0827>.
- [25] Brodsky SL, Lichtenstein B. The gold standard and the pyrite principle: toward a supplemental frame of reference. *Front Psychol* 2020;11:562. <https://doi.org/10.3389/fpsyg.2020.00562>.
- [26] Schoenthaler M, Wilhelm K, Katzenwadel A, et al. Retrograde intrarenal surgery in treatment of nephrolithiasis: is a 100% stone-free rate achievable? *J Endourol* 2012;26:489–93. <https://doi.org/10.1089/end.2011.0405>.
- [27] Yu Y, Chen Y, Zhou X, et al. Comparison of novel flexible and traditional ureteral access sheath in retrograde intrarenal surgery. *World J Urol* 2024;42:7. <https://doi.org/10.1007/s00345-023-04697-1>.